

TOXOPNEUSTES PILEOLUS

PROVING OF THE POISONOUS BUT EDIBLE "FLOWER"-URCHIN

presented by Jörg Hildebrandt, MD, Austria
www.dr-hildebrandt.at

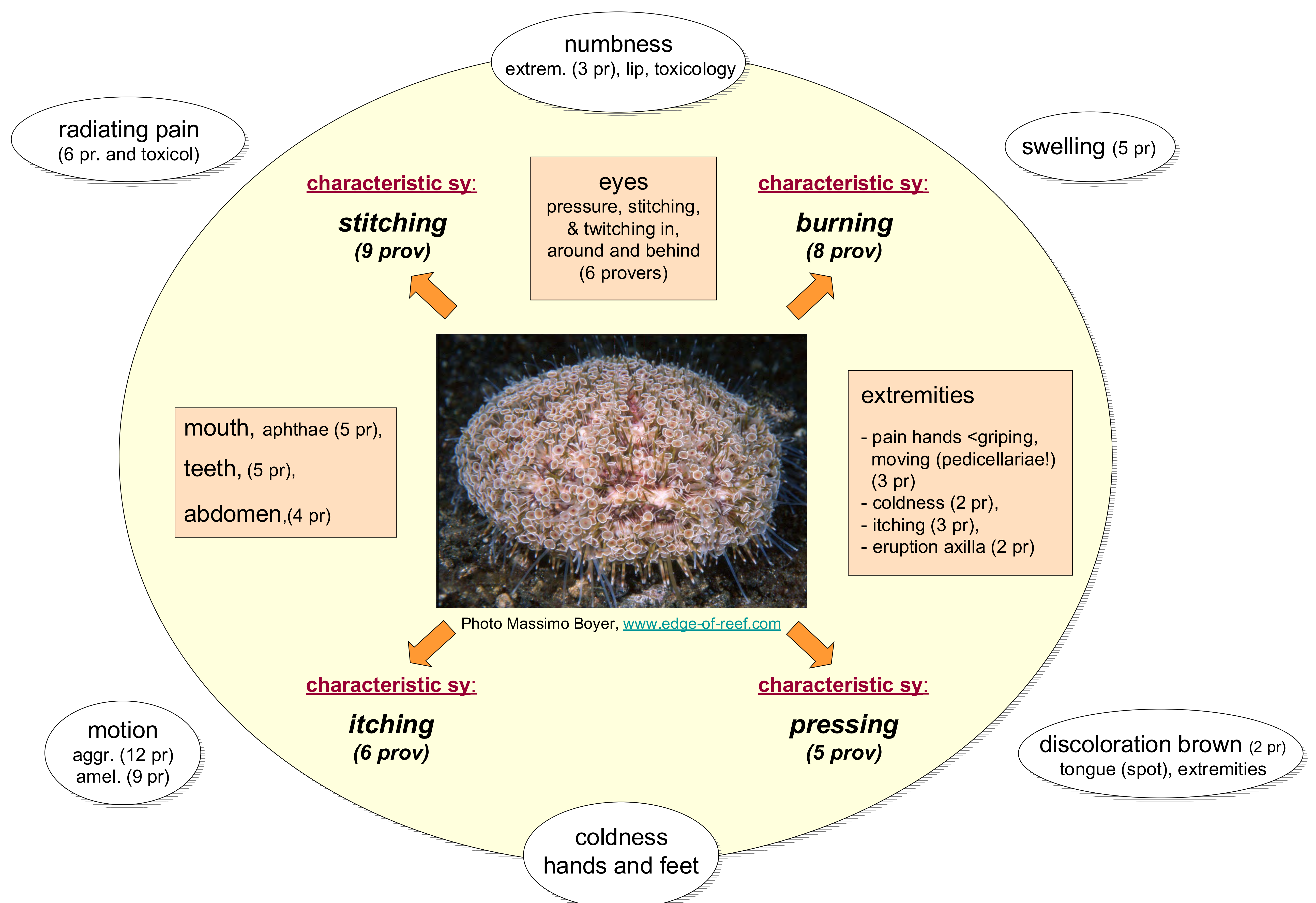
This is a report of the first proving of a member of the sea urchins, which is *Toxopneustes pileolus* (toxop). The (sometimes) edible *Toxopneustes* is exceptional because of its small spines but poisonous claws (giving the flower-appearance). The 5 streaks of gonads in its body are edible (raw) – but during some seasons poisonous. The urchin usually hides by covering itself with pieces of corals and stones.

I collected a *Toxopneustes* during a diving expedition to the island Bohol/Philippines in March 1998. A part of the top of its shell (anus) and a part of its strong shell with spines, pedicellariae (=poisonous claws) and still moving "feet" were taken and immediately triturated to the first C-potency, later potentized to 30 CH (C30) and 200 CH (C200) by Mag. Robert Müntz, Salvator Pharmacy Eisenstadt, where the remedy can be ordered (robert.muentz@remedia.at)

14 healthy provers (13 verum C30 or C200, one placebo) between 21 and 49 years of age and one patient provided symptoms. For one prover the remedy was her simile. The double-blind proving took place from June 1998 to August 1999, with the provers starting separately.

Migraine, radiating back pain, stitching pain and numbness of the extremities are some of the prominent symptoms.

Normalization of elevated antinuclear antibodies (ANA) could be observed in a patient.



Prover's simile: 26yrs old female prover: rather healthy, but often migraine right forehead, like "an abscess in the brain, pulsating from within outwards"; old skin eruption at the margin of her hair (for more than 10 years resistant to any non-homeopathic therapy), always cold hands and feet. On the same day after taking her first (and only) dose, her hands began to become warm, the skin eruption receded within 4 days, the migraine disappeared. Old problems (a big mountain which I didn't want to see) came up and brought a great deal of changes in her life. But her symptoms disappeared for 6 years.

Patient: woman, 36 yrs: after myomectomy and sterilisation: migraine, which she suffered from for years and headache, that she had since childhood disappeared. A few months after the operation: reduced vision, supraorbital pain right side, and decreasing concentric restricted visual field with elevated ANA (antinucleotid antibodies). Cold hands and feet, pulsating headache right forehead from within outward.

Toxop. C12 brought back the old migraine immediately, healed the neuralgia, ameliorated vision (not visual field), warmed hands, and in C 200 and higher reduced ANA to normal. Polychrests given to reduce headache, raised the ANA titre quickly. Meanwhile she got higher potencies and got rid of the headaches and migraine as well (3 years observation).